

# Anomalous features of iliac vein stenosis that affect diagnosis and treatment

Seshadri Raju, MD, FACS, and Micah Davis, BS, Jackson, Miss

**Background:** Endovenous management of venous lesions is largely derived from arterial experience. However, venous lesions, particularly iliac vein stenoses, differ from their arterial counterparts in some crucial respects. Awareness of these differences is necessary for proper diagnosis and treatment. This report expands on three such anomalous features that we have noted previously in anecdotal form: (1) a unique form of a long and diffuse stenosis (Rokitansky stenosis) that may escape diagnosis with conventional techniques; (2) the invariable failure of plain old balloon angioplasty (POBA) to relieve iliac vein stenosis (both focal and diffuse); and (3) the stent compression by venous strictures, whether focal or diffuse, extrinsic to the stent. Although these features are somewhat interrelated from the concentric fibrous structure of iliac vein stenosis, they represent different phases in the overall management of iliac vein lesions.

**Methods:** The analyses are derived from electronic medical records of 2534 iliac vein stent procedures performed from 1996 to 2013. Smaller subsets were used to record more detailed intravascular ultrasound planimetry data than were available in the generic database.

**Results:** The incidence of Rokitansky stenosis without focal lesions was 1.5%. After POBA, stenotic area increased from

a median of 60 mm<sup>2</sup> to 62 mm<sup>2</sup>, a miniscule improvement. Lumen area increased to a nearly “normal” 172 mm<sup>2</sup> after stent placement. In 103 limbs with residual or recurrent symptoms, in-stent restenosis (ISR) was present in all limbs; additional stent compression was evident in 25% of the limbs, adding to the overall severity of the stenosis. ISR responded well to high-pressure balloon dilation, with total clearance in 62% of treated limbs and substantial improvement in others. In contrast, stent compression was resistant, remaining unchanged in 68% after balloon dilation.

**Conclusions:** Rokitansky stenosis is easily missed with conventional diagnostic techniques and may not be recognizable even with intravascular ultrasound, unless routine planimetry is used. POBA as a primary treatment invariably fails to correct focal or diffuse iliac vein stenosis, and stenting is always required. Stent compression is a unique feature of iliac vein stenosis, whether it is focal or diffuse. It often occurs in association with ISR, when overall stenosis can be underestimated if stent compression is not taken into account. Stent compression responds poorly to balloon dilation, whereas the associated ISR shows complete clearance in the majority of treated limbs. (J Vasc Surg: Venous and Lym Dis 2014;2:260-7.)

Iliac vein stenting is of recent vintage, and many of the endovenous techniques are a carryover from prior arterial experience. However, the morphologic and pathologic features of venous lesions are different from those of arterial stenosis. These result in differences in presentation, response to treatment, and postoperative complications not usually seen in arterial experience. Awareness of these anomalous features and appropriate modification of standard practice used in arterial applications are necessary for optimal results. We focus on three such unique features of iliac vein stenosis that we have reported in short form previously.<sup>1,2</sup> Data in greater detail than before are presented here to elaborate on these unique features that affect the diagnosis and treatment of iliac vein stenoses. Although these features are loosely interrelated to the

fibrous nature of iliac vein stenoses, they represent different aspects of managing these lesions.

A feature of iliac vein stenosis is the occurrence of a special form of post-thrombotic stenosis that is long and diffuse. Lacking diagnostic cues such as focal narrowing and collaterals on venograms, the lesion is often missed. First described by Rokitansky in the 18th century from autopsy studies, the lesion arises from development of a fibrotic sleeve that envelops long segments of the iliac vein and retards collateral development; the fibrotic sleeve produces luminal stenosis from perivenous restriction. There were even early attempts to relieve this form of stenosis by surgical excision of the restrictive envelope. One way to identify this unique lesion is to institute routine measurement of lumen diameter or area in diagnostic studies. This is impossible in routine diagnostic venography but may be possible (yet to be proven) with high-resolution magnetic resonance imaging or computed tomography. Intravascular ultrasound (IVUS) planimetry provides a convenient way to identify and to treat this lesion with IVUS-guided stent placement in a single session.

We have previously reported in anecdotal form that iliac venous stenosis, whether focal or diffuse, responds poorly to plain old balloon angioplasty (POBA), unlike its arterial counterpart.<sup>3</sup> This is related to concentric fibrosis present

From The Rane Center at St. Dominic Hospital.

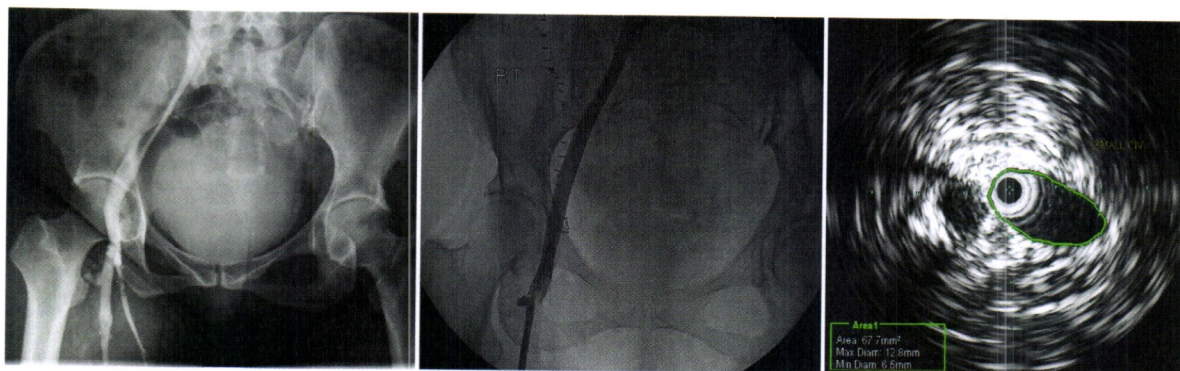
Author conflict of interest: S.R. has stock in Veniti and holds a U.S. patent for intravascular ultrasound diagnosis in veins.

Reprint requests: Seshadri Raju, MD, FACS, The Rane Center at St. Dominic Hospital, 971 Lakeland Dr, East Tower, Ste 401, Jackson, MS 39216 (e-mail: rajumd@earthlink.net).

The editors and reviewers of this article have no relevant financial relationships to disclose per the Journal policy that requires reviewers to decline review of any manuscript for which they may have a conflict of interest. 2213-333X/\$36.00

Copyright © 2014 by the Society for Vascular Surgery.

<http://dx.doi.org/10.1016/j.jvsv.2013.12.004>



**Fig 1.** Venographic appearance of “classic” Rokitsky stenosis (**left**). The constricted lumen of the iliac vein is unmistakable. However, venographic appearance may be “normal” in other cases (**middle**). On intravascular ultrasound (IVUS) examination, the common iliac vein in this patient was diffusely narrow (**right**), measuring only  $12.8 \times 6.5$  mm in its greatest and least diameters. The elliptical shape probably explains normal venographic appearance. The lumen area of the common iliac vein in undiseased normals is  $\approx 200$  mm<sup>2</sup>. The lesion in this patient measured 67 mm<sup>2</sup> and represents 66% stenosis.

in iliac vein stenosis that resists POBA, whereas the eccentric fibrosis underneath arteriosclerotic plaques allows its successful use.<sup>4</sup> Furthermore, venography, which is the assessment modality practiced in many institutions, is poorly sensitive to estimation of stenoses.<sup>5,6</sup> POBA continues to be practiced in venous stenoses, in part owing to ostensible improvement observed on venography. We present herein precise intraoperative IVUS measurements to show that POBA nearly always fails to relieve iliac vein stenosis and recoil is invariable. Improvement in degree of stenosis, if any, is marginal and clinically insignificant. This means that stenting should always be used in venous stenoses as the primary treatment modality from the outset.

Another feature related to the circumferential nature of venous fibrosis in iliac vein stenoses is stent compression. This occurs from fibrous strictures, whether focal or diffuse, in the native vein compressing the stent from outside, causing the stent lumen to narrow. This, too, is rarely seen in arterial experience, and if it occurs, it is not severe enough to curtail distal perfusion. In contrast, diameter reduction from stent compression may result in peripheral venous hypertension.<sup>2</sup> The degree of stent compression can be assessed with IVUS planimetry. Whereas the incidence of severe stent compression alone is low, it is usually associated with in-stent restenosis (ISR) in symptomatic limbs. This combination can result in underestimation of ISR and total lumen reduction by standard measurement technique. A method of considering both elements in computing stent stenosis is described.

## METHODS

**Patients.** Summary information about all stent procedures, from 1996 to the present, had been maintained in an electronic database. The incidence of Rokitsky stenosis among all limbs newly treated ( $n = 2534$ ) was derived from this database. Smaller series of treated limbs in 2011-2012 were used for the POBA and stent compression

analyses as IVUS data entered into the larger database were not sufficiently detailed. For POBA, a consecutive series of 47 primary interventions (limbs) was used; for stent compression, a consecutive series of 103 reinterventions (limbs) to correct functional stent failure was used. The sample sizes were statistically adequate to support the conclusions presented.

**Indications for stent placement and reinterventions.** Patients with highly symptomatic chronic venous disease resistant to conservative therapy were treated with IVUS-guided stent placement as described in detail previously.<sup>7</sup> Reinterventions were carried out to correct functional stent failure in patients with residual or recurrent symptoms. Poor function of the stent, commonly due to ISR or stent compression, is often associated with inflow or outflow stenosis.<sup>2</sup> Preoperative imaging studies and venography may confirm the presence of such stent abnormalities, but IVUS remains the final diagnostic arbiter.

**Stenting technique.** Atlas balloons (Bard Peripheral Vascular, Tempe, Ariz), 16 mm in size, were used to predilate the lesion to 16 atm as described in detail elsewhere.<sup>8,9</sup> Because recoil was invariable, as documented by POBA results later, 18-mm stents (slightly oversized) were

**Table I.** Demographics

	POBA ( $n = 48$ ) ISR ( $n = 99$ )	
Median age, years (range)	66 (28-97)	59.5 (22-86)
Male:female	1:3	1:3
Right limb:left limb	1:2	1:1
PTS:MTS	4:1	3:1
CIV limbs, No. (%)	17 (35)	8 (8)
EIV limbs, No. (%)	25 (52)	87 (88)
Both CIV and EIV limbs, No. (%)	6 (13)	4 (4)

CIV, Common iliac vein; EIV, external iliac vein; ISR, in-stent restenosis; MTS, May-Thurner syndrome; PTS, post-thrombotic syndrome; POBA, plain old balloon angioplasty.



**Table II.** Area change after plain old balloon angioplasty (POBA) in iliac vein stenosis

<i>n</i> = 48 <sup>a</sup>	Area, mm <sup>2</sup> , median (range)	Increase from base area	P value
Base area (before balloon dilation)	60 (23-76)	—	—
Area after balloon dilation	62 (21-140)	3%	.07
Area after stent placement	172 (122-317)	186%	<.0001 <sup>b</sup>

<sup>a</sup>Data missing in four limbs.<sup>b</sup>Statistically significant.

routinely placed across the lesion but were postdilated to only 16 mm. Wallstents (Boston Scientific, Natick, Mass) were used exclusively. During reinterventions to correct functional stent failure, 18-mm Atlas balloons were used to dilate areas of stent compression and ISR repeatedly until maximum possible stent expansion and ISR resolution had been achieved.

**IVUS planimetry.** IVUS catheters (6F) were used. The equipment (Volcano Corporation, San Diego, Calif) incorporated diameter and area measurements with an electronic pen. Because the technique is pixel-based, machine variability between procedures is negligible. Intraprocedural measurements were carried out by IVUS-trained technicians who were unaware of this analysis. Inherent observer error in outlining the lesion was not minimized by receiver operating characteristic filters in this study.

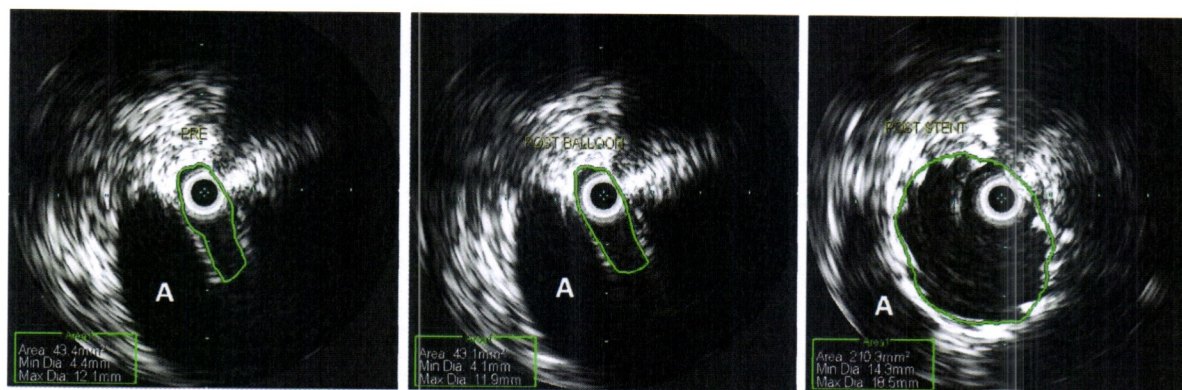The degree of stenosis (percentage stenosis) was based on area measurements, not diameter. In calculation of percentage stenosis, the poststented lumen area was used as the denominator ("normal" area) and the stenosis area at its narrowest as the numerator. This methodology was used in estimating Rokitansky stenosis and POBA results. Special modifications are suggested in case of stent compression and ISR as described next.

Stent compression results from stricture of the native vein *external* to the stent (focal or diffuse), causing it to narrow, as distinguished from ISR, which occurs *internal* to the stent. In case of stent compression that develops over time, the degree of stent compression could be

calculated from the stent areas measured during the original procedure and during subsequent reintervention. It was the difference in stent areas between the two procedures expressed as a percentage of the original stent area. To measure the area enclosed within the stent, the inner perimeter of the stent was traced by the electronic pen, adjusting the gain setting as needed for adequate resolution. In case of immediate stent compression resulting from an unyielding stenosis during the initial procedure, nominal values of expected lumen size based on diameters of 16, 14, and 12 mm for the common iliac, external iliac, and common femoral veins, respectively, were used in calculating stent compression.

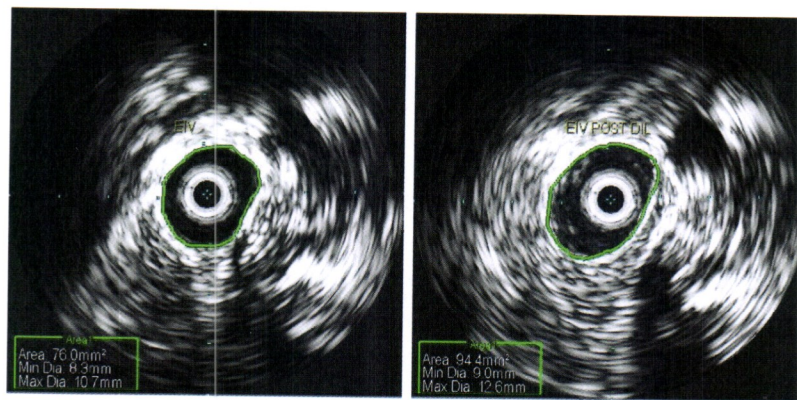
The traditional methodology to measure ISR by IVUS planimetry is to draw the area encompassed by the stent perimeter with the electronic pen and then the lumen area within the ISR to calculate the percentage stenosis. A better method to account for stent compression when it is present with ISR is to consider residual lumen area as a fraction of stent lumen area recorded during the original procedure (or nominal values for the location, if greater).

**Statistics.** Individual data are given as median with range unless otherwise indicated. Paired and unpaired values were analyzed by nonparametric two-tailed Wilcoxon rank test and Mann-Whitney test. Statistical significance was defined as a *P* value < .05. All analyses were performed with Prism software (Prism Software Corporation, Irvine, Calif).



**Fig 2.** Plain old balloon angioplasty (POBA) in May-Thurner type of stenosis. The measured area of the stenosis behind the artery (A) was exactly the same (43 mm<sup>2</sup>) before and after balloon dilation (left and middle). After stent placement (right), the lumen area measured 210 mm<sup>2</sup>, which is normal.





**Fig 3.** Post-thrombotic external iliac vein (EIV) stenosis improved from 76 mm<sup>2</sup> (left) to 94 mm<sup>2</sup> (right) after plain old balloon angioplasty (POBA). This is well below normal; external iliac vein lumen size is  $\approx 154$  mm<sup>2</sup> (14-mm diameter). Note perivenous fibrosis.

## RESULTS

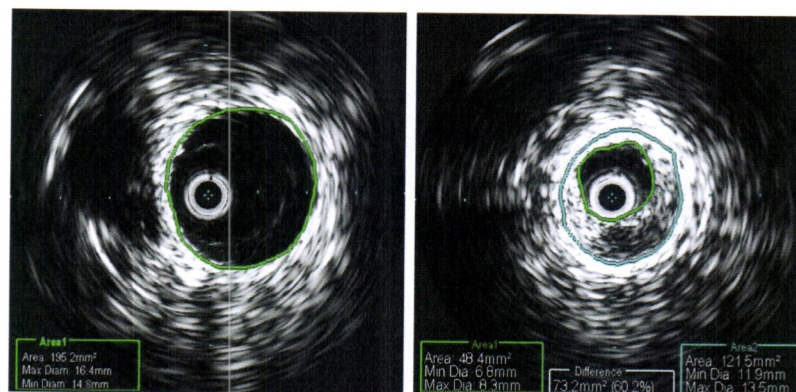
**Rokitansky stenosis.** The overall incidence of this characteristically long and diffuse lesion was 1.5% (38 of 2534) among stented limbs. Median area stenosis was 55% (28%-95%). The lesion was occasionally apparent on venography but more frequently was not. The lesion is readily identifiable on IVUS measurements (Fig 1).

**POBA.** The demographics of the POBA subset are shown in Table I. Post-thrombotic limbs were more common than nonthrombotic limbs. The IVUS planimetry areas before and after POBA in iliac vein stenoses are shown in Table II. Representative examples of the POBA result in iliac vein stenoses are shown in Figs 2 and 3. The median area improvement after POBA in iliac vein stenoses was a miniscule 3%, not likely to yield clinical benefit. In 21% of limbs, luminal area at the stenotic site was the same as before; and in 20%, it was actually worse (smaller) after POBA, suggestive of a component of spasm. Improvement of the stenotic area of >50% after POBA occurred in only 4% of the balloon-dilated limbs. There was not a single

limb in the subset in which the post-POBA area equaled poststent area (representing normal area for the location).

**Stent compression.** The overall incidence of stent compression in 103 limbs undergoing reinterventions was 25% (26 limbs), with 19 being mild (<20% compression). There were six (6%) limbs with 20% to 50% compression and one limb with 73% compression. Compression occurred in post-thrombotic limbs as well as in nonthrombotic limbs ( $P = .2$ ). Stent compression most frequently occurred in the external iliac vein segment, and its incidence in common iliac veins was relatively rare (Table I).

All of the 103 limbs undergoing reinterventions had ISR, 26 with stent compression and 77 without. Significant stent compression can underestimate overall stent stenosis if the compressive element is not taken into account (Fig 4). The 26 limbs with combined stent compression and ISR and the 77 limbs with ISR alone were treated with high-pressure (16 atm) Atlas balloons. ISR in both groups responded well to balloon dilation (Table III); it was completely cleared in 61 limbs, with the remaining



**Fig 4.** Stented area (common iliac vein) at the initial procedure was 195 mm<sup>2</sup> (left). Stent compression and in-stent restenosis (ISR) occurred 5 months later (right). ISR was 60% by traditional calculation. When stent compression is taken into account, overall lumen stenosis was calculated to be 75%.



**Table III.** Improvement in stent compression and in-stent restenosis (ISR) after balloon dilation

<i>n</i> = 99	Stent compression	ISR
Parameter	Stent area, mm <sup>2</sup>	Stenosis, %
Before balloon dilation, median (range)	183 (59-419)	55 (0-91)
After balloon dilation, median (range)	168 (52-350)	0 (0-64)
<i>P</i> value	<.0001 <sup>a</sup>	<.0001 <sup>a</sup>

<sup>a</sup>Statistically significant.

38 limbs showing median residual ISR of 38% (8%-64%). In contrast, stent compression was highly resistant to high-pressure balloon dilation. Of the 26 limbs with stent compression so treated, only 8 limbs showed improvement of at least 10%; the remaining 18 limbs showed little change (Fig 5). Overall, median stent compression was slightly worse ( $P < .0001$ ) after balloon dilation.

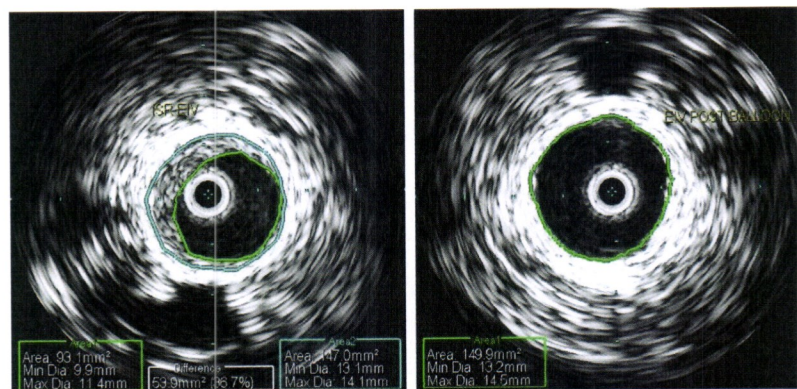
## DISCUSSION

All the anomalous features of iliac vein stenosis presented here are related to its specific morphology but intricately connected to the pathophysiologic mechanism of venous obstruction, which differs from that of arterial stenosis in fundamental ways. The basis of symptoms in arterial stenosis is inadequate perfusion, and the aim of treatment is to restore in-line flow. In contrast, upstream (peripheral) hypertension is the source of symptoms in chronic venous disease; stenotic lesions of <50% in iliac veins can be symptomatic, less than the stenotic threshold seen in symptomatic arterial lesions.<sup>10,11</sup> The aim of treatment is to decompress the peripheral veins, which requires use of large stents (much larger in arterial applications) approximating normal anatomic size. In our experience, the iliac veins are remarkably uniform in caliber in normal-sized adults with variation of no more than  $\pm 10\%$ . Teleologically, this is essential to maintain peripheral venous pressure

(also constant) at homeostatic levels. As a rough guide, the following diameter/area parameters are appropriate for the location in normal-sized adults: 16 mm/200 mm<sup>2</sup> for the common iliac vein; 14 mm/150 mm<sup>2</sup> for the external iliac vein; and 12 mm/125 mm<sup>2</sup> for the common femoral vein.

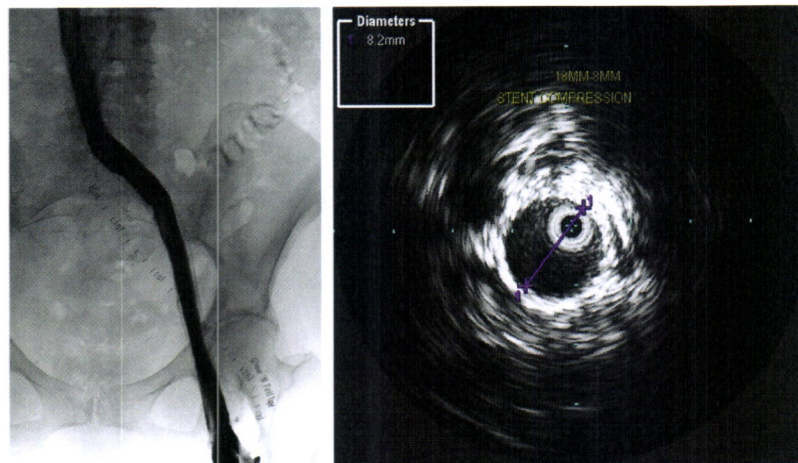
The muscle content of venous wall progressively decreases in the cephalad direction; muscle orientation also gradually changes from circular to helical or longitudinal.<sup>12</sup> The iliac veins are nearly "pure" collagen tubes with little concentric muscle content. The inferior vena cava is thicker and more muscular. These physical properties exhibit different pressure-volume curves.<sup>13</sup> Being extremely thin-walled, the iliac veins are "full" with as little as  $\approx 2$  mm Hg pressure, and further increase in pressure results in little increase in volume because of the near absence of elastin in the wall.<sup>12-14</sup> On IVUS examination in the supine position, the iliac veins are fully distended at normal filling pressures with little respiratory variation; the inferior vena cava is partially collapsed and exhibits cyclic area changes with cardiac and respiratory action. Stenoses that occur in the iliac veins or at the iliac-caval junction are usually "fixed" with no phasic area changes. In occasional instances, when this occurs, the *larger* of the two measured areas of the stenosis at each end of the respiratory cycle is used in percentage stenosis calculations. Because the abdominal veins are enclosed within the pressurized abdominal cavity, which behaves like a fluid-filled chamber, transmural pressures within the abdominal veins remain unchanged with a change in posture. This means that estimates of iliac vein stenoses obtained in the supine position are likely to be valid in the erect position as well.

One other practical point to be noted pertains to balloon dilation and stenting. We routinely use a 16-mm balloon for the entire iliac-caval-femoral segment for economy and place a slightly oversized 18-mm stent stack during the initial procedure for later hyperdilation if the need arises. Nevertheless, the stent always reverts to the nominal diameter of the various vein segments because of recoil of the tough adventitia, and the radial force of the Wallstent is not enough to overstretch it. However, a smaller than normal stent lumen area (stent



**Fig 5.** The stent combined compression and in-stent restenosis (ISR) (left) showed complete resolution of ISR after balloon dilation (right), but mild stent compression persisted. EIV, External iliac vein.





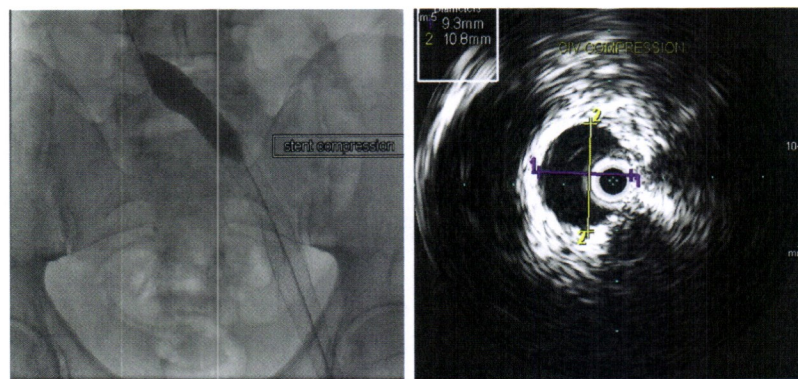
**Fig 6.** Preintervention venography (**left**) in a patient with symptoms of stent malfunction showed patent stent with mild in-stent restenosis (ISR). Severe stent compression was found (**right**) during reintervention. An 18-mm Wallstent balloon (Boston Scientific, Natick, Mass) dilated to 16-mm diameter was compressed to 8 mm. Stent compression is relatively resistant to balloon dilation, as shown in [Table III](#).

compression) may sometimes occur from recoil of unyielding stenoses during the initial procedure. This means that post-stent area can be conveniently used in calculating percentage stenosis unless there is stent compression, in which case nominal areas for the location should be used in calculations.

Inadequate correction of stenoses with undersized stents typically results in residual symptoms, although patency may be retained. In reinterventions, an effort is made to restore lumen area to the threshold values to relieve residual symptoms. The importance of recognizing the stent compressive element during reinterventions is directly relevant to this point. Although severe stent compression (>50%) is rare, its frequent occurrence in association with ISR renders even a milder degree of stent compression a significant factor in estimating overall lumen stenosis. Stent compression, even when it is severe, is seldom apparent on venography, mainly because of the

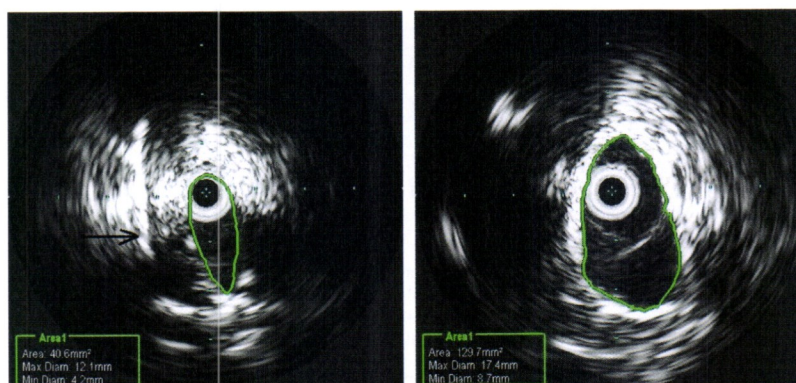
lack of an integrated measurement scale unaffected by magnification and parallax. Duplex ultrasound has potential if good image quality can be obtained but has not been tested in assessing stent compression. For the present, IVUS with integrated planimetry remains the preferred technique ([Fig 6](#)). Not only post-thrombotic disease but also nonthrombotic May-Thurner lesions can cause stent compression ([Fig 7](#)). Stent compression is difficult to correct with balloon dilation as recoil is invariable. However, balloon dilation is worthwhile as the associated ISR responds well, providing relief of the ISR-related stenotic component but not of the compressive element.

There are morphologic differences (IVUS) in the fibrous structure of arterial and venous stenoses, although the venous lesions have not been studied in depth, unlike arterial lesions. In arteries, it is eccentric and may not occupy all quadrants; and when it is circumferential, there



**Fig 7.** Stent compression caused by May-Thurner type of lesion. A 16-mm balloon shows waisting in dilation of stent compression (**left**). The compressed stent diameter measured 11 × 9 mm on intravascular ultrasound (IVUS) examination (**right**). Expected normal diameter in this location is ≈ 16 mm.





**Fig 8.** Subclavian vein stenosis associated with a valve apparatus (**left**). The *arrow* points to dilated valve annulus. Prestenotic dilation is present with a stenotic valve aperture outlined. Plain old balloon angioplasty (POBA) resulted in tripling of the lumen size from 40 mm<sup>2</sup> to 129 mm<sup>2</sup> (**right**), which is in the normal range. Clinical improvement was transient, however.

are breaks in between.<sup>4</sup> These characteristics allow lumen restoration by balloon angioplasty through fracture of the plaque and wall.<sup>15,16</sup> Post-thrombotic iliac vein strictures are formed from concentric intramural and perivenous fibrosis as seen in Fig 3. In nonthrombotic disease, wall fibrosis results from trauma of repeated pulsations of the intimately related artery; in addition, anatomic structures (arteries, ligaments, bone) provide a relatively unyielding scaffold.<sup>17</sup> Although eccentric in their compressive effects, these natural elements are resistant to balloon dilation (Fig 2). In this consecutive POBA subset, 20% of limbs had nonthrombotic etiology (Table I). Recoil rather than yield after balloon angioplasty is the rule in both venous pathologic processes. Stents are therefore routinely required to correct iliac vein stenosis. Any improvement of balloon angioplasty alone seen on venography is likely to be spurious in most instances. An element of spasm was evident after balloon dilation. Because area measurements were made immediately before and after balloon dilation, it is plausible but unlikely that POBA-mediated stenotic correction would have become evident later. Most of the patients treated with POBA alone from our very early experience and others treated elsewhere have been stented since, with relief of persistent symptoms.

Rokitansky-type stenosis can occur with or without focal lesions in association. Whereas its incidence without focal elements highlighted here is relatively low, it is estimated that 10% to 20% of post-thrombotic stenoses have diffuse stenotic involvement of adjoining venous segments. Its recognition is therefore important so that involved segments can be adequately stented. The long length of Rokitansky stenoses (not a factor in most arterial stenoses) adds to the severity of stenoses (Poiseuille law). This may be important at the margins in lesions that would be considered minor otherwise. There have been attempts to assess severity of iliac vein stenosis by methods such as magnetic resonance imaging.<sup>18</sup> It is likely that the diffuse element in iliac vein stenoses may be missed in these imaging modalities as well, unless routine diameter measurements are

included in interpretations. Because coronal crosscuts in magnetic resonance imaging and computed tomography pass at a tangent to the iliac vein axis and the lesions often occur at the angular iliac-caval junction, there are other potential sources of error in interpretation. Postprocessing of images (three-dimensional reconstruction) offers potential promise, but the technique is not suitable for intraprocedural use. For the present, IVUS remains the tool of choice for diagnosis and to guide stent placement that can be carried out concurrently with prior consent of the patient.

The special features characteristic of iliac vein stenoses may not be applicable to venous lesions in other locations. Stent treatment typically yields inferior results elsewhere in the upper body. In the subclavian vein, two types of stenoses appear to occur: a regular post-thrombotic lesion that often spans the first rib and another more central one away from the first rib, where stenoses are associated with valve apparatus (Fig 8). Thickening and sclerosis of valve cusps, which sometimes are fused to form a small aperture, can be seen on IVUS examination. Precise causation (congenital or developmental) is not known. Prestenotic and poststenotic dilation may be present. POBA of such lesions appears to provide modest dilation without recoil during the procedure. In a limited experience (nine limbs), clinical relief after POBA was temporary and symptoms recurred within several weeks. The subclavian lesions bear similarities to internal jugular vein lesions associated with multiple sclerosis.<sup>19,20</sup>

## AUTHOR CONTRIBUTIONS

Conception and design: SR  
Analysis and interpretation: SR, MD  
Data collection: SR, MD  
Writing the article: SR  
Critical revision of the article: SR  
Final approval of the article: SR  
Statistical analysis: SR, MD  
Obtained funding: SR  
Overall responsibility: SR

## REFERENCES

1. Neglen P, Raju S. Intravascular ultrasound scan evaluation of the obstructed vein. *J Vasc Surg* 2002;35:694-700.
2. Raju S, Tackett P Jr, Neglen P. Reinterventions for nonocclusive iliofemoral venous stent malfunctions. *J Vasc Surg* 2009;49:511-8.
3. Neglen P, Raju S. Balloon dilation and stenting of chronic iliac vein obstruction: technical aspects and early clinical outcome. *J Endovasc Ther* 2000;7:79-91.
4. Stary HC, Chandler AB, Dinsmore RE, Fuster V, Glagov S, Insull W Jr, et al. A definition of advanced types of atherosclerotic lesions and a histological classification of atherosclerosis. A report from the Committee on Vascular Lesions of the Council on Arteriosclerosis, American Heart Association. *Circulation* 1995;92:1355-74.
5. Raju S, Oglesbee M, Neglen P. Iliac vein stenting in postmenopausal leg swelling. *J Vasc Surg* 2011;53:123-30.
6. Negus D, Fletcher EW, Cockett FB, Thomas ML. Compression and band formation at the mouth of the left common iliac vein. *Br J Surg* 1968;55:369-74.
7. Neglen P, Hollis KC, Olivier J, Raju S. Stenting of the venous outflow in chronic venous disease: long-term stent-related outcome, clinical, and hemodynamic result. *J Vasc Surg* 2007;46:979-90.
8. Neglen P, Berry MA, Raju S. Endovascular surgery in the treatment of chronic primary and post-thrombotic iliac vein obstruction. *Eur J Vasc Endovasc Surg* 2000;20:560-71.
9. Raju S, Neglen P. Percutaneous recanalization of total occlusions of the iliac vein. *J Vasc Surg* 2009;50:360-8.
10. Raju S, Kirk O, Jones T. Endovenous management of venous leg ulcers. *J Vasc Surg Venous Lymphat Disord* 2013;1:165-73.
11. Raju S, Kirk O, Davis M, Olivier J. Hemodynamics of "critical" venous stenosis and stent treatment. *J Vasc Surg Venous Lymphat Disord* 2014;2:52-9.
12. Attinger EO. Wall properties of veins. *IEEE Trans Biomed Eng* 1969;16:253-61.
13. Strandness DE, Sumner DS. Hemodynamics for surgeons. Grune & Stratton: New York; 1975.
14. Moreno AH, Katz AI, Gold LD, Reddy RV. Mechanics of distension of dog veins and other very thin-walled tubular structures. *Circ Res* 1970;27:1069-80.
15. Chin AK, Kinney TB, Rurik GW, Shoor PM, Fogarty TJ. A physical measurement of the mechanisms of transluminal angioplasty. *Surgery* 1984;95:196-201.
16. Dzau VJ, Gibbons GH. Vascular remodeling: mechanisms and implications. *J Cardiovasc Pharmacol* 1993;21(Suppl 1):S1-5.
17. May R, Thurner J. The cause of the predominantly sinistral occurrence of thrombosis of the pelvic veins. *Angiology* 1957;8:419-27.
18. Marston W, Fish D, Unger J, Keagy B. Incidence of and risk factors for ilioacaval venous obstruction in patients with active or healed venous leg ulcers. *J Vasc Surg* 2011;53:1303-8.
19. Zamboni P, Galeotti R, Menegatti E, Malagoni AM, Tacconi G, Dall'Ara S, et al. Chronic cerebrospinal venous insufficiency in patients with multiple sclerosis. *J Neurol Neurosurg Psychiatry* 2009;80:392-9.
20. Zamboni P, Galeotti R, Weinstock-Guttman B, Kennedy C, Salvi F, Zivadinov R. Venous angioplasty in patients with multiple sclerosis: results of a pilot study. *Eur J Vasc Endovasc Surg* 2012;43:116-22.

Submitted Jul 12, 2013; accepted Dec 20, 2013.